ISI–PAOLO VI · ROME 2026

The Role of Surgery in Restoring Natural Fertility

Luis López-Fando Lavalle, MD, PhD

DIP. DI MEDICINA - DIMED
UNIVERSITÀ DEGLI STUDI DI PADOVA

UNIVERSITÀ DEGLI STUDI DI PADOVA

Urolf

FERTILITAS

SURGERY & NATURAL FERTILITY

The question is not simply “can we operate?”

RESTORE

Correct a reversible cause so fertilisation can occur in vivo.

- Surgical management aims to allow **natural conception**
- **Microsurgery** is essential (Robotic)
- Correct **patient selection** and **surgeon experience** are critical for success.

SURGERY & NATURAL FERTILITY

Operate on the couple, not on the semen analysis

Male diagnosis	Semen analysis · physical examination · hormones · genetics when indicated
Female prognosis	Age · ovarian reserve · timing · coexisting factors
Shared goals	Natural conception · acceptable wait · risks · ART preferences

SURGERY & NATURAL FERTILITY

Where can surgery restore natural fertility?

Sperm production

Repair a palpable clinical varicocele in selected infertile men.

Sperm transport

Vasovasostomy or epididymovasostomy in reconstructable obstruction.

Distal outflow

Incise an obstructed ejaculatory duct or unroof a compressive midline cyst.

EAU Guidelines on

Male Infertility

A. Jungwirth (Chair), T. Diemer (Vice-chair), G.R. Dohle, Z. Kopa, C. Krausz, H. Tournaye

© European Association of Urology 2016

Table 3 – European Association of Urology guideline recommendations for specific male infertility conditions[a]

Recommendation	Strength rating
Do not use hormonal treatment for cryptorchidism in postpubertal men.	Strong
If undescended testes are corrected in adulthood, perform simultaneous testicular biopsy for detection of intratubular germ cell neoplasia in situ (formerly carcinoma in situ).	Strong
Men with unilateral undescended testis and normal hormonal function/spermatogenesis should be offered orchidectomy.	Strong
Men with unilateral or bilateral undescended testis with biochemical hypogonadism and or spermatogenic failure (ie, infertility) may be offered	Weak
Men wi al risk factors, as this may result in early detectio	Weak
Do not perform testicular biopsy, follow-up scrotal ultrasound, biochemical measurement of tumour markers, or abdominal or pelvic computed tomography in men with isolated TM without associated risk factors (eg, infertility, cryptorchidism, testicular cancer, and atrophic testis).	Strong
Testicular biopsy may be offered to infertile men with TM in one of the following higher risk groups: spermatogenic failure (infertility), bilateral TM, atrophic testes (<12 ml), history of undescended testes, or TGCT.	Weak
If there are suspicious findings on physical examination or ultrasound in patients with TM with associated lesions, perform inguinal surgical exploration with testicular biopsy or offer orchidectomy after a multidisciplinary team meeting and discussion with the patient.	Strong
Men treated for TGCT are at higher risk of developing hypogonadism, sexual dysfunction, and cardiovascular disease. Men should be managed in a multidisciplinary team setting with a dedicated late-effects clinic.	Weak
Sperm cryopreservation should be performed before planned orchidectomy, since men with testis cancer may have significant semen abnormalities (including azoospermia).	Weak
Men wit abnormalities may be offered oncotesticular sperm extraction at the time of radical o	Weak
Treat inf men parameters, or otherwise unexplained infertility in a couple in which the female partner has a good ovarian reserve to improve the fertility rate.	Strong
Varicocelectomy may be considered in men with raised SDF with otherwise unexplained infertility or who have suffered from failed ART, including recurrent pregnancy loss or failure of embryogenesis and implantation.	Weak
MAGI treatment may improve sperm quality, although it does not necessarily improve the probability of conception.	Weak
The data are insufficient to conclude whether antibiotics and antioxidants for the treatment of infertile men with leucocytospermia will improve fertility outcomes.	Weak
Refer sexual partners of patients with a MAGI known or suspected to be caused by sexually transmitted diseases for evaluation and treatment.	Strong

ART = assisted reproductive techniques; MAGI = male accessory gland infection; SDF = sperm DNA fragmentation; TGCT = testicular germ cell tumour; TM = testicular microcalcification.

[a] Amended table from the European Association of Urology guidelines on sexual and reproductive health [6].

DIAGNOSTIC: TESTICULAR BIOPSY

VARICOCELECTOMY

EAU Guidelines on

Male Infertility

A. Jungwirth (Chair), T. Diemer (Vice-chair), G.R. Dohle, Z. Kopa, C. Krausz, H. Tournaye

Table 5 – Recommendations for the surgical management of infertility[a]

Recommendation	Strength rating
Perform microsurgical vasovasostomy or epididymovasostomy for azoospermia caused by epididymal or vasal obstruction in men with female partners with good ovarian reserve.	Strong
Use sperm re… SPERM CONDUCT RECONSTRUCTION …sperm extraction, and percutaneous techniques, ei… …to surgical repair, or when the ovarian reserve of the … …ction and the couple prefer to proceed to ICSI treatment directly.	Strong
Patients with NOA should undergo a comprehensive assessment, including detailed medical history, hormonal profile and genetic tests to investigate the underlying aetiology and associated comorbidities. Genetic counselling is mandatory in couples with genetic abnormalities prior to any assisted reproductive technology protocols.	Strong
Surgery for sperm retrieval can be performed in men who are candidates for ART (ie, ICSI). For patients with complete *AZFa* and *AZFb* microdeletions, surgery is contraindicated since the chance of sperm retrieval is zero.	Strong
FNA and TESA should not be considered the treatments of choice in patients with NOA, given the lower probability of positive sperm retrieval compa… SPERM RETRIEVAL TECHNIQUES	Weak
FNA as a progn… …A is not recommended for use in routine clinical practice.	Weak
Conventional or microdissection TESE is the technique of choice for retrieving sperm in patients with NOA.	Weak
No preoperative biochemical and clinical variables can be considered sufficient and reliable predictors of positive sperm retrieval at surgery for patients with NOA.	Weak
No conclusive recommendations can be made regarding routine use of medical therapy (eg, recombinant FSH; highly purified FSH; human chorionic gonadotropin; aromatase inhibitors or selective oestrogen receptor modulators) in patients with NOA before TESE.	Weak

ART = assisted reproductive techniques; FNA = fine needle aspiration; FSH = follicle-stimulating hormone; ICSI = intracytoplasmic sperm injection; NOA = nonobstructive azoospermia; TESA = testicular sperm aspiration; TESE = testicular sperm extraction.

[a] Amended table from the European Association of Urology guidelines on sexual and reproductive health [6].

FERTILITAS

Diagnostic procedures:

Testicular biopsy

Testicular sperm aspiration

FERTILITAS

Procedures to improve sperm production:

Varicocele repair

FERTILITAS

Procedures to improve sperm delivery:

Vasectomy reversal

FERTILITAS

Sperm retrieval procedures

vasal aspiration of sperm

Epididymal aspiration of sperm

Open testis biopsy

Testis sperm aspiration & needle biopsy

FERTILITAS

Surgical management of ejaculatory duct obstruction:

Transurethral resection of ejaculatory duct

Transurethral balloon dilatation of ejaculatory duct

FERTILITAS

Diagnostic procedures:

Testicular biopsy

Testicular sperm aspiration

FERTILITAS

Procedures to improve sperm production:

Varicocele repair

FERTILITAS

Procedures to improve sperm delivery:

Vasectomy reversal

FERTILITAS

Sperm retrieval procedures

vasal aspiration of sperm

Epididymal aspiration of sperm

Open testis biopsy

Testis sperm aspiration & needle biopsy

FERTILITAS

Surgical management of ejaculatory duct obstruction:

Transurethral resection of ejaculatory duct

Transurethral balloon dilatation of ejaculatory duct

Diagnostic Surgery in Male Infertility

- Diagnostic surgery plays a crucial role in the evaluation of azoospermia, particularly in distinguishing between obstructive and non-obstructive causes.
- The two main diagnostic tools are testicular biopsy and Fine Needle Aspiration (FNA) with or without mapping.
- **FNA +- Mapping** is minimally invasive and offers >90% correlation with biopsy

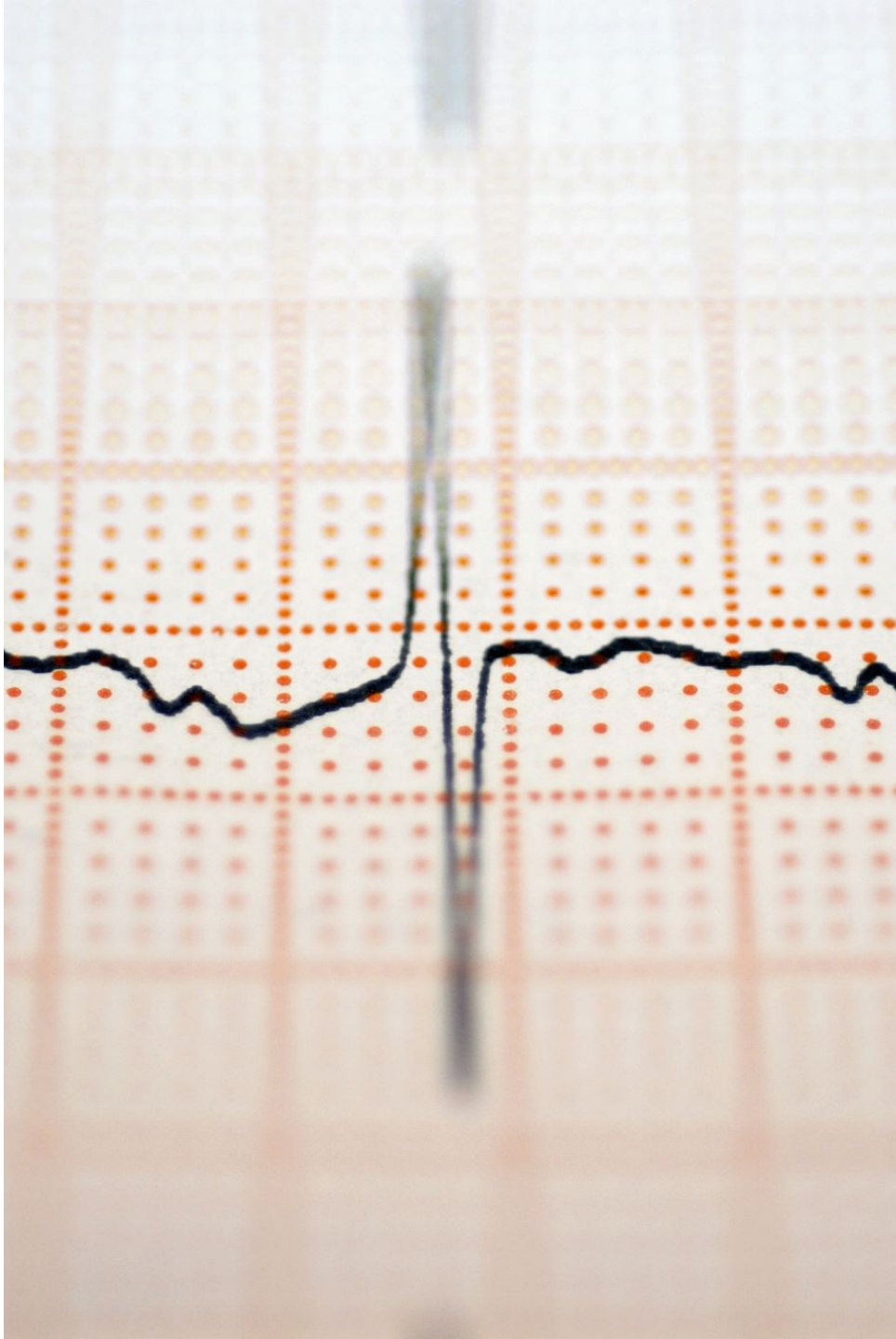



✅ Biopsy Recommended (Strong Evidence)

Adult men with a history of undescended testes:
Perform simultaneous testicular biopsy to detect intratubular germ cell neoplasia (formerly carcinoma in situ).

Men with suspicious testicular lesions (found on physical exam or ultrasound):
Perform inguinal surgical exploration with biopsy or orchiectomy after multidisciplinary discussion.

⚠️ Biopsy May Be Considered (Weak Recommendation)

Infertile men with testicular microlithiasis (TM) and at least one of the following high-risk factors:

- **Spermatogenic failure (infertility)**
- Bilateral TM
- Atrophic testes (<12 mL)
- History of undescended testes
- Personal or family history of TGCT (testicular germ cell tumor)

❌ Biopsy Not Recommended (Strong Evidence)

Men with isolated TM and no risk factors (e.g., no infertility, no history of undescended testes,no atrophy):
Do not perform testicular biopsy; use follow-up imaging and tumor markers instead.

Testicular Biopsy	**5**	Mature teratoma.	1
		No tumor. Hipoespermatogenesis	2
		Leydig cell tumor	1
		After FNA: Sertoli Cell.	1

Urolf

FERTILITAS

Testicular Fine Needle Aspiration (FNA)

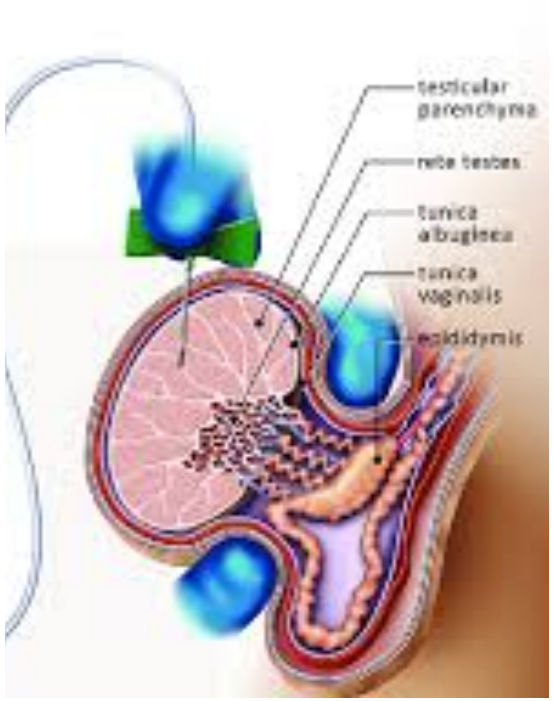

Minimally invasive alternative to diagnostic testicular biopsy.

Used in **azoospermic men** to identify focal areas ("pockets") of sperm production.

Mapping First introduced for mapping by Turek et al. in 1997.

Helps guide future sperm retrieval or treatment decisions.

Advantages:

1. No incision required.
2. Minimal morbidity.
3. Can sample **multiple regions** of the testis.
4. 90% histological correlation with open biopsy.

Based on 72 testicles from 50 patients (bilateral and unilateral procedures)

Diagnosis	Nº Testes	% (out of 72)	Literature Range
Normal spermatogenesis	6	8.3%	15–40%
Hypospermatogenesis	31	43.0%	5–15%
Maturation arrest	10	13.9%	20–40%
Sertoli cell-only (pure)	17	23.6%	20–35%
Non-diagnostic / insufficient	8	11.1%	

Future: Robotic-assisted FNA con IA



Microsurgery in Male Infertility and Andrology

Fig. 5. Doppler evaluation of the spermatic cord vessels. (*A*) VTI audio micro-Doppler probe. (*B*) Aloka visual micro-Doppler probe.

seen in sperm count and/or motility in 76% of the patients who had oligospermia; 28% of patients with preoperative azoospermia were found to have sperm in their ejaculate 6 months postoperatively. Pain scores were also significantly decreased in 92% of patients who had testicular pain preoperatively. Eighty-four percent of these patients with testicular pain had also undergone robotic-assisted targeted microsurgical denervation of the spermatic cord during the varicocelectomy.

Mechlin and McCullough[11] recently also showed comparable outcomes with robotic varicocelectomy. They also found that the robotic approach provided a more controlled training environment for residents and fellows to advance their microsurgical and robotic skills.[11]

ROBOTIC-ASSISTED MICROSURGICAL TESTICULAR SPERM EXTRACTION

crosurgical testicular sperm extraction (micro-`E) has the highest sperm retrieval rates among `s sperm retrieval techniques in patients with `tructive azoospermia.[12] The use of robotic `e for micro-TESE provides the surgeon `ne simultaneous imaging of the testic- `aluation by the embryologist while `operating. This capability is helpful `s or tubules that may be more `. As future sperm imaging `olve (such as probe- `roscopy and multi- `his technology `atform

Technique and Outcomes

The procedure is performed with the patient in the supine position. The testicles are delivered through a midline scrotal incision and the da Vinci robotic platform is docked from the patient's right side after the testicular tunica is incised. Black Diamond Micro Forceps, bipolar microforceps, and the Potts scissors are loaded into the right, left, and the fourth arms, respectively. The surgeon view on the robotic console is seen in Fig. 6. The microsurgeon can easily identify dilated seminiferous tubules with the da Vinci 3-dimensional camera and the extramagnified VITOM image, and simultaneously evaluate the tissues sampled by the embryologist using the 100× phase-contrast microscope.

New imaging technology is being developed that may better identify tubules that harbor sperm during micro-TESE.[13,14] The robotic platform would provide an ideal platform for the integration of these types of adjunctive tools.

ROBOTIC-ASSISTED MICROSURGICAL TARGETED DENERVATION OF THE SPERMA CORD

Microsurgical denervation of the sperm (MDSC) is a viable surgical treatme chronic groin or scrotal content Chronic groin or scrotal cor defined as pain that is unil mittent or constant, ar in the groin ar

Robotic-Assisted Microsurgical Testicular Sperm Extraction



FERTILITAS

Diagnostic procedures:

Testicular biopsy

Testicular sperm aspiration

FERTILITAS

Procedures to improve sperm production:

Varicocele repair

FERTILITAS

Procedures to improve sperm delivery:

Vasectomy reversal

FERTILITAS

Sperm retrieval procedures

vasal aspiration of sperm

Epididymal aspiration of sperm

Open testis biopsy

Testis sperm aspiration & needle biopsy

FERTILITAS

Surgical management of ejaculatory duct obstruction:

Transurethral resection of ejaculatory duct

Transurethral balloon dilatation of ejaculatory duct

VARICOCELE REPAIR:



- **Varicocele** is an abnormal dilation of the pampiniform plexus veins within the scrotum.

- It is the **most common surgically correctable cause** of male infertility.

- Present in ~15% of the general male population and up to **40% of men with infertility**.

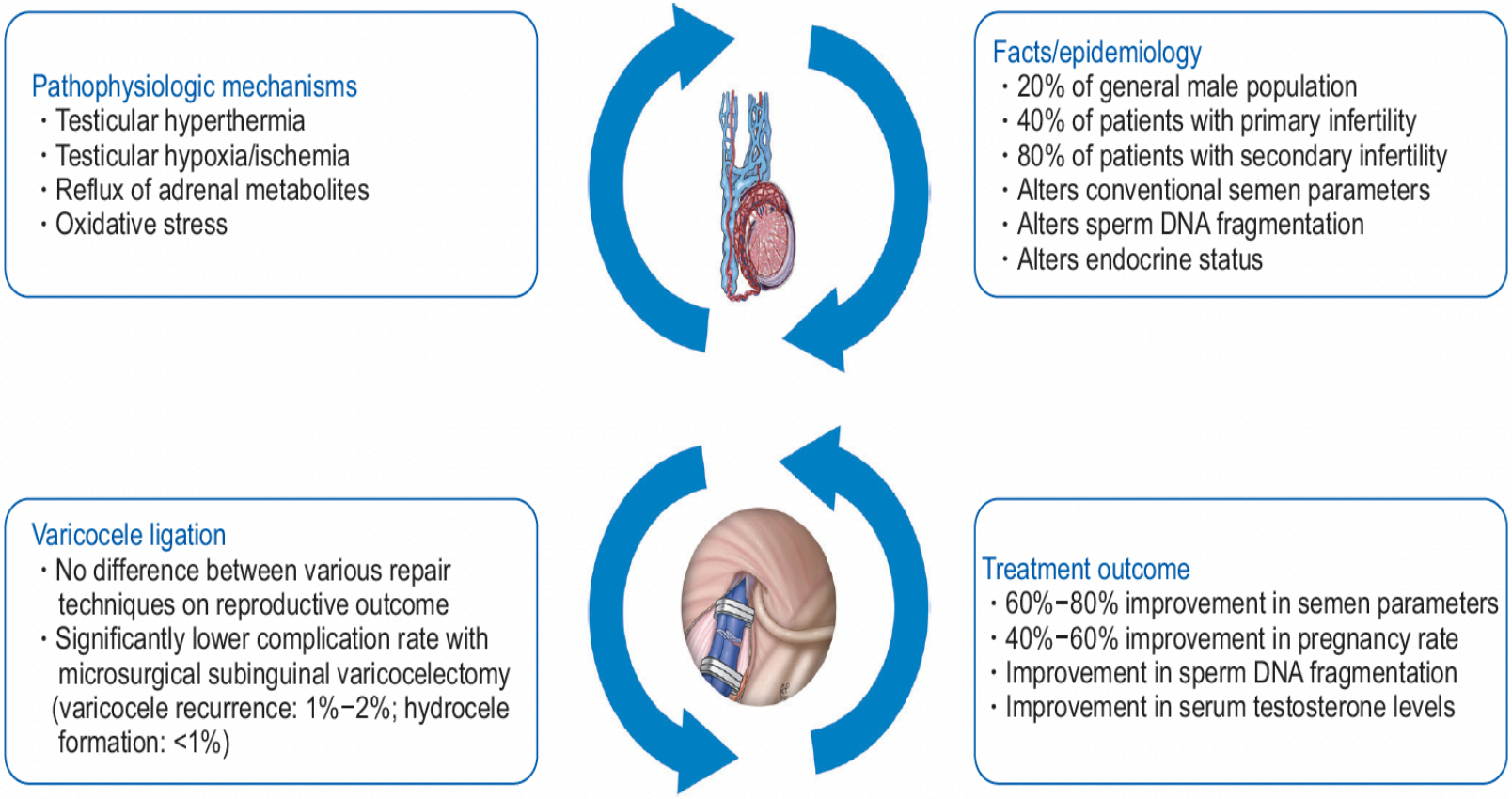

Fig. 14. Varicocele.

Ashok Agarwal, et al: Schematic Overview of Male Infertility Practice

Journal of
Clinical Medicine

MDPI

Review

Varicocele: To Treat or Not to Treat?

Antonio Franco [1], Flavia Proietti [2,*], Veronica Palombi [2], Gabriele Savarese [2], Michele Guidotti [3], Costantino Leonardo [2], Fabio Ferro [4], Claudio Manna [5] and Giorgio Franco [2]

Varicocelectomy improves semen parameters and pregnancy rate when properly indicated.

Key factor: patient selection is critical for success.

Adolescent treatment aims to preserve testicular function.

Adults: focus on current fertility improvement.



STRONG

OPERATE	Clinical palpable varicocele + abnormal semen + otherwise unexplained infertility + good ovarian reserve
DO NOT OPERATE ?¿	Normal semen analysis or subclinical varicocele
ADOLESCENTS	Persistently smaller testis (>2 mL or 20%), confirmed twice 6 months apart

The recommendation is phenotype-based, not driven by Doppler imaging alone.

Diagnostic Doppler correlates for varicocele

>3 mm

Venous diameter

Standing, during Valsalva

>2 s

Venous reflux duration

During Valsalva

Doppler is particularly valuable when examination is inconclusive or recurrence is suspected.

VARICOCELE REPAIR:

Indications for Treatment

1. Clinical varicocele (palpable on physical exam) **with abnormal semen parameters**.
2. Adolescents with varicocele and **testicular growth arrest**.
3. Selected cases of **non-obstructive azoospermia** (NOA): subclinical varicocele

Urolf

FERTILITAS

Microsurgical subinguinal varicocelectomy

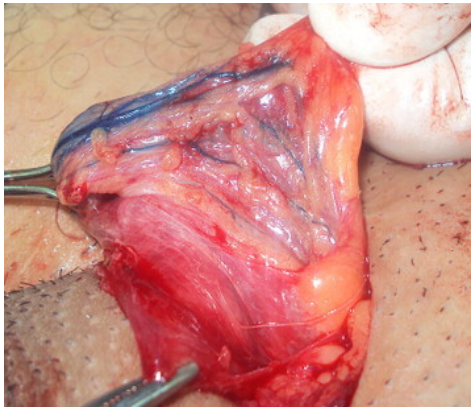

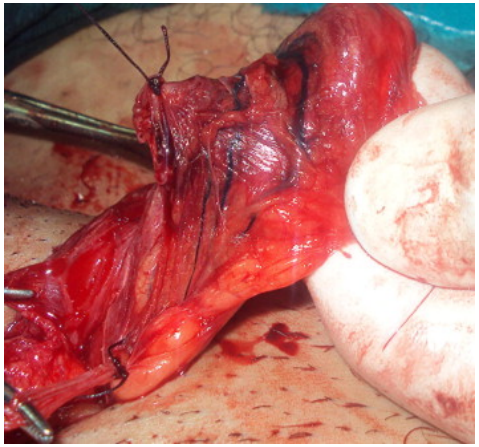



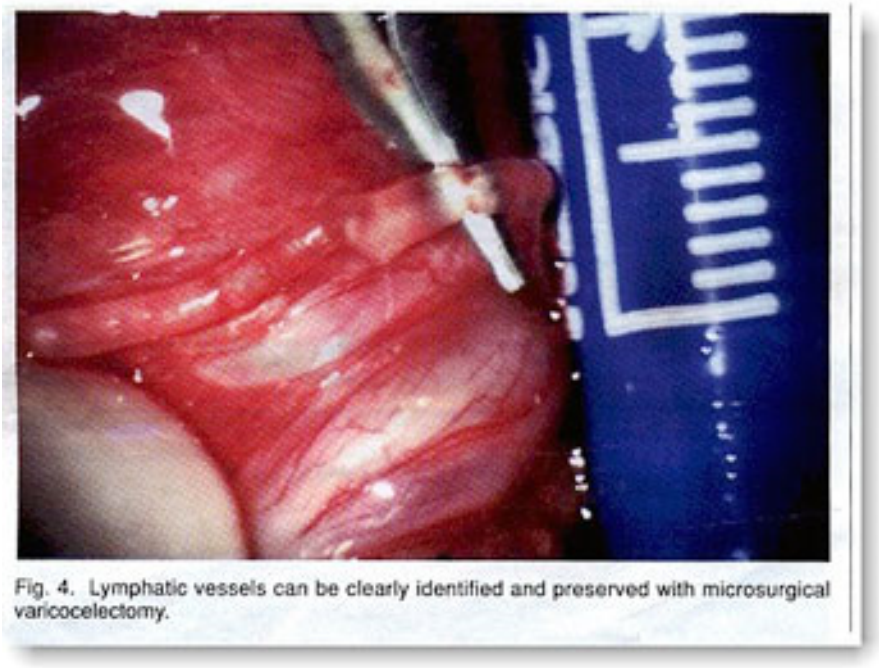

Fig. 4. Lymphatic vessels can be clearly identified and preserved with microsurgical varicocelectomy.

Comparison of Techniques

Technique	Artery Preserved	Hydrocele (%)	Failure (%)	Potential for Serious Morbidity
Retroperitoneal	No	7	15–25	No
Conventional inguinal	No	3–30	5–15	No
Laparoscopic	Yes	12	3–15	Yes
Radiographic	Yes	0	15–25	Yes
Microscopic inguinal or subinguinal	Yes	0	1.0	No

Cochrane Library
Trusted evidence.
Informed decisions.
Better health.

Cochrane Database of Systematic Reviews

Varicocelectomy: evidence and realistic expectations

PREGNANCY

RR 1.55

95% CI 1.06–2.26

Cochrane review (2021)

- May improve natural pregnancy vs. no/ delayed treatment
- Semen improvement often needs 3–6 months
- Most pregnancies are observed later, around 6–12 months

EAU Guidelines on Sexual and Reproductive Health, March 2026, sections 11.3–11.6

Utilizes an operating microscope for arterial preservation and lymphatic sparing.

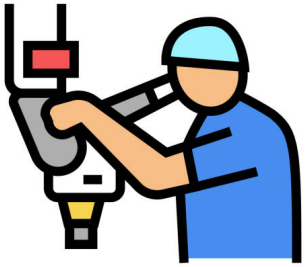

Lower risk of recurrence and complications (e.g., hydrocele) compared to other methods.

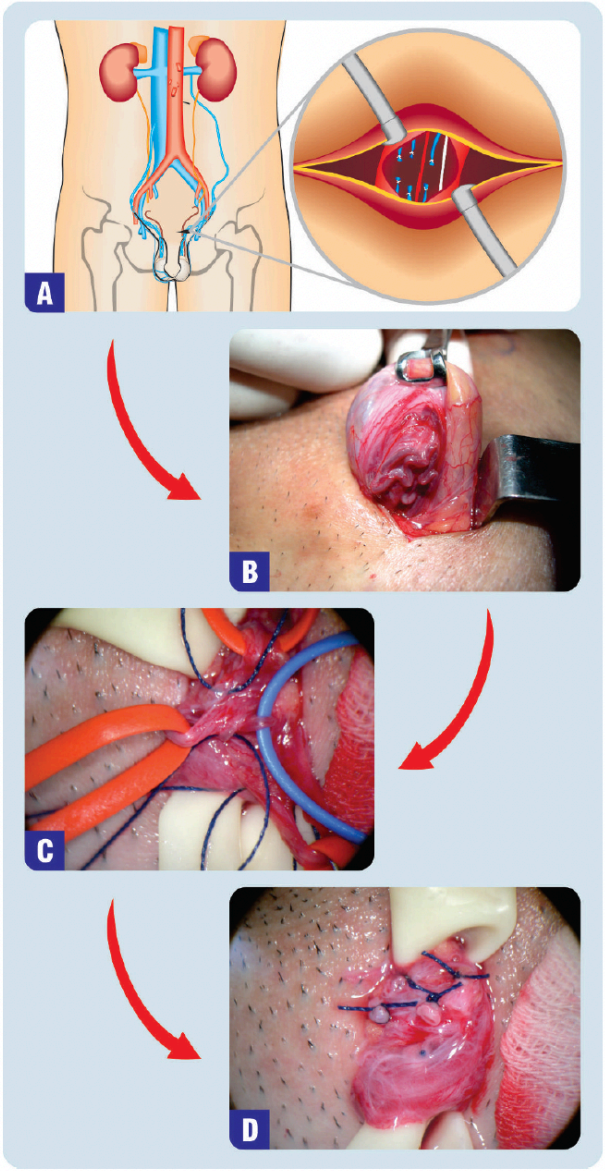

Figure 1 - Microsurgical Subinguinal Varicocele Repair. A) A transverse incision is made just below the level of the external inguinal ring. B-D) Intraoperative photographs of the spermatic cord. B) Dilated cremasteric veins are identified by elevating the spermatic cord with a Babcock clamp. C) Testicular artery (blue vessel loop), lymphatics (blue cotton suture), and dilated varicose veins (red vessel loops) are demonstrated. D) Final surgical aspects of the varicose veins are transected and ligated with nonabsorbable sutures.


CM
1
2
3
4
5



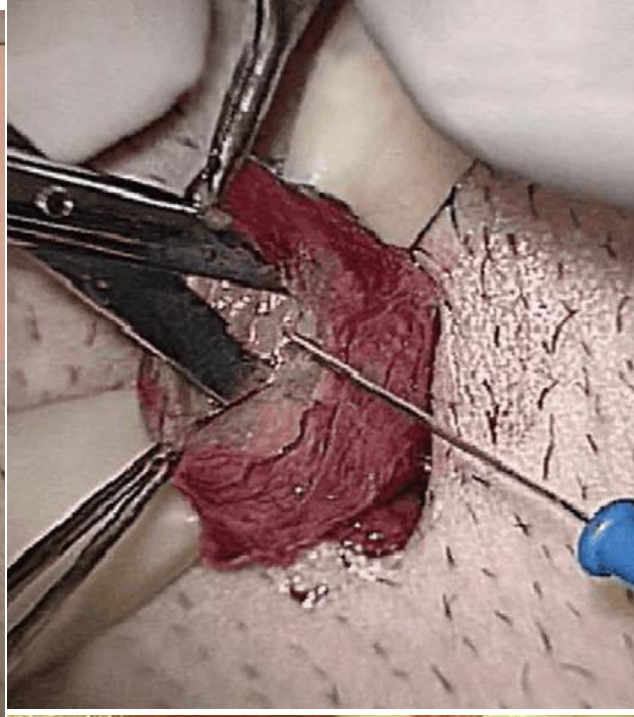

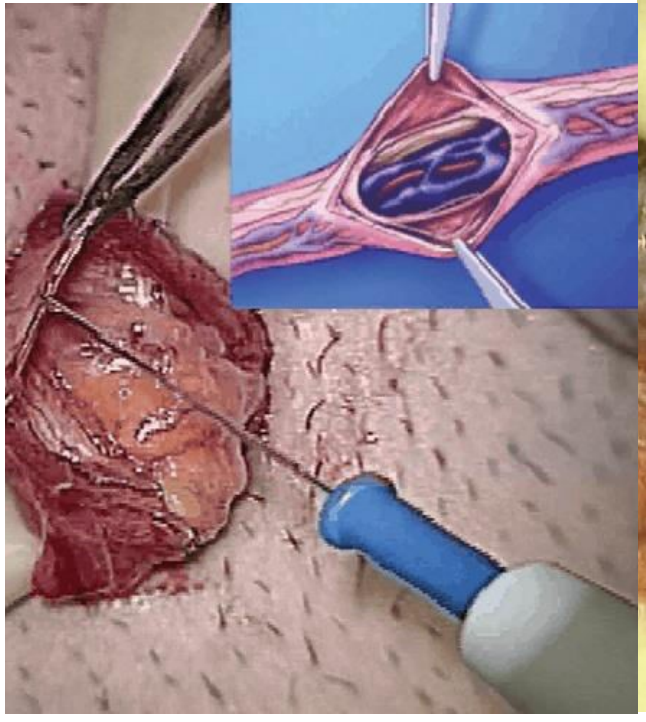

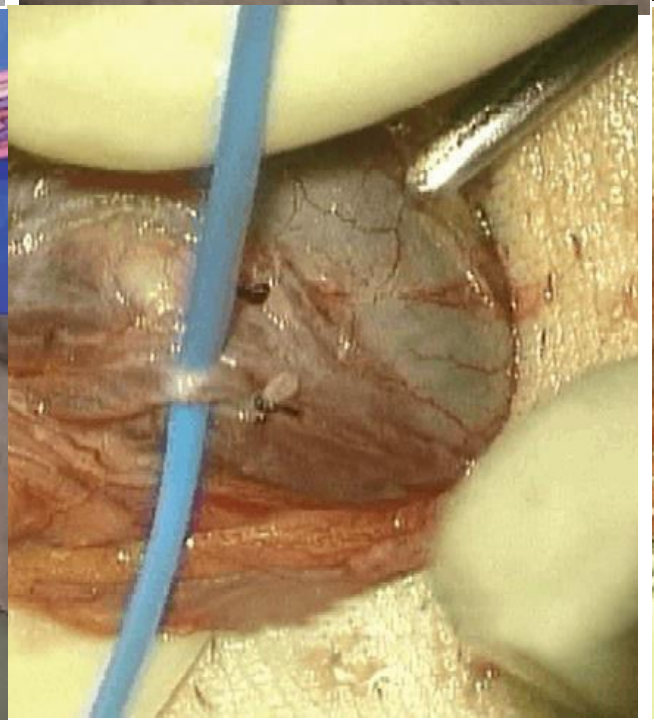

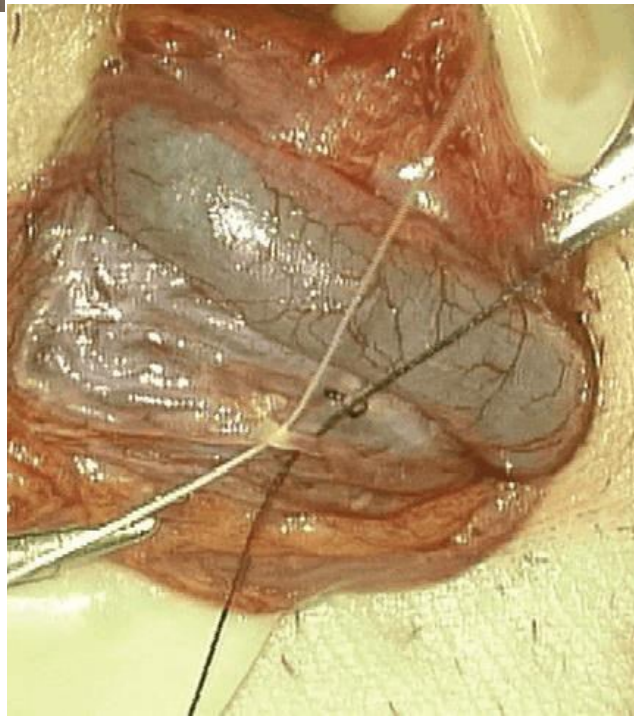

Outcomes

63 cases

2018-2025

Improvement in semen parameters in 60–80% of men.

70%

Spontaneous pregnancy rates range from 20–60% depending on population and study.

14 pregnancy

In azoospermic men, ~30–50% may have sperm appear in the ejaculate postoperatively.

Improves outcomes of ART by increasing sperm quality and possibly reducing the need for testicular sperm extraction.

VARICOCELE / NOA

Varicocelectomy in NOA: promising, low certainty

43.9%

Sperm detected in ejaculate after repair

Range 20.8–55.0% · observational data

INTERPRETATION

Meta-analyses suggest improved sperm retrieval, but evidence quality is low and benefit to natural conception is unproven.

Reappearance of sperm ≠ spontaneous pregnancy.

EAU Guidelines on Sexual and Reproductive Health · March 2026 · §11.4.3.c.3, p.144

VARICOCELE / SDF

Raised sperm DNA fragmentation: selective use

CONSIDER REPAIR

Clinical varicocele with raised SDF in otherwise unexplained infertility or after ART failure / recurrent pregnancy loss.

WEAK

COUNSELL FIRST

Exclude other causes of SDF, discuss female ovarian reserve and potential delay before ART.

EAU: “may be considered” — not a routine universal indication.

Cost effectiveness



The cost is less when compared with IVF- ICSI



Follow up:

Semen analysis 4 months after varicocelectomy

Semen to be monitored regularly for at least 1 year or until pregnancy is achieved

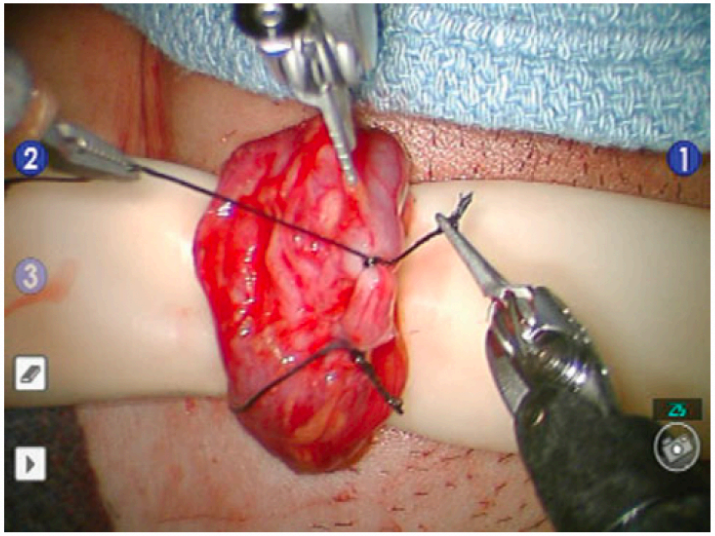

Robotic-Assisted Microsurgical Subinguinal Varicocelectomy

Indication: Clinical varicocele in men with infertility or scrotal pain.

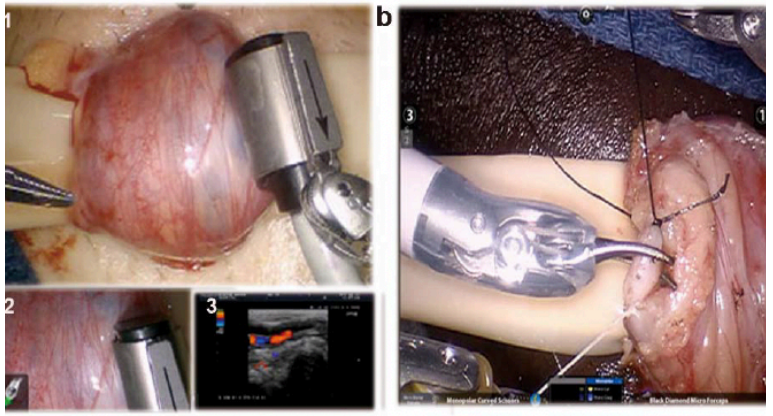

•**Advantages**:

Enhanced precision during vein ligation.

Simultaneous use of micro-Doppler with robotic arms.

Reduces risk of artery or lymphatic injury.

Better ergonomics for the surgeon.

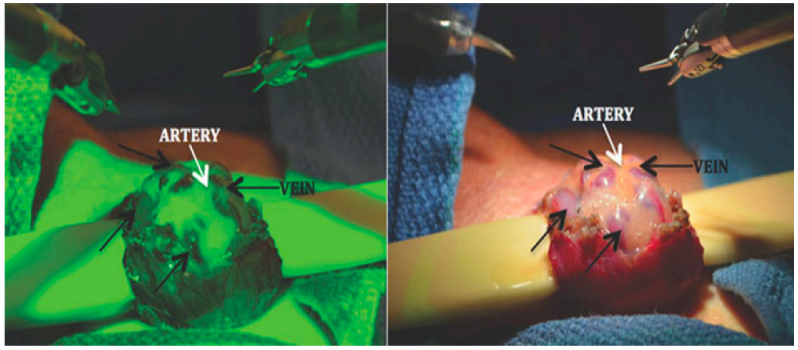

•**Outcomes**:

76% showed improved semen parameters.

28% of azoospermic men had return of sperm in ejaculate.

92% of men with testicular pain had symptom improvement.

VARICOCELE / TECHNOLOGY

Robot-assisted varicocelectomy: similar success

CURRENT EAU POSITION

Robot-assisted varicocelectomy has a similar success rate to microsurgical varicocelectomy.

THE EVIDENCE GAP

Larger prospective randomized studies are still needed to identify the most effective approach.

Do not present the robotic approach as superior for natural pregnancy.

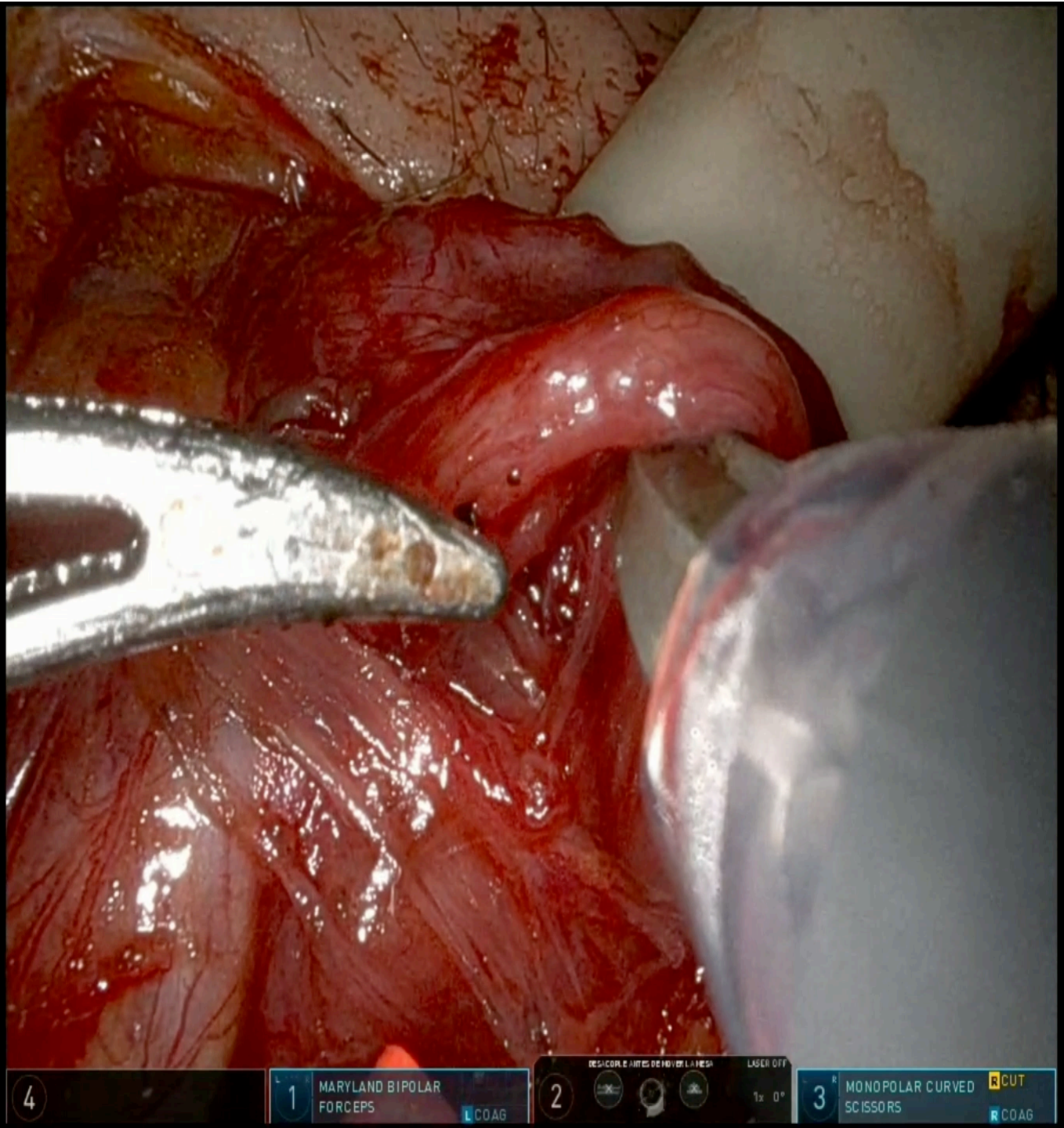
4
1
MARYLAND BIPOLAR
FORCEPS
L COAG
2
DESACOPLE ANTES DE MOVER LA MESA
LASER OFF
1x 0°
3
MONOPOLAR CURVED
SCISSORS
R CUT
R COAG

Received: 30 August 2024 | Accepted: 4 February 2025
DOI: 10.1002/uro2.70003

UroPrecision Open Access

REVIEW ARTICLE

Artificial intelligence and varicocelectomy: A new horizon for patient management? A narrative review

Oussama G. Nasrallah[1] | Moustafa A. Al Hattab[2] | Bassel G. Bachir[1]



AI-based models outperform traditional nomograms in predicting semen improvement.

Machine learning tools (e.g., Ory, Kandevani models) reach AUC > 0.70.

Inputs include age, hormone profile, testicular volume, DNA fragmentation.

Personalized decision-making may reduce overtreatment and improve satisfaction.

FERTILITAS

Diagnostic procedures:

Testicular biopsy

Testicular sperm aspiration

FERTILITAS

Procedures to improve sperm production:

Varicocele repair

FERTILITAS

Procedures to improve sperm delivery:

Vasectomy reversal

FERTILITAS

Sperm retrieval procedures

vasal aspiration of sperm

Epididymal aspiration of sperm

Open testis biopsy

Testis sperm aspiration & needle biopsy

FERTILITAS

Surgical management of ejaculatory duct obstruction:

Transurethral resection of ejaculatory duct

Transurethral balloon dilatation of ejaculatory duct

Obstruction of the Epididymis and Vas Deferens

1. Major cause of obstructive azoospermia (OA).
2. Most common cause: vasectomy; others include infection, congenital absence, iatrogenic injury.
3. Normal spermatogenesis but no sperm in ejaculate due to blockage.

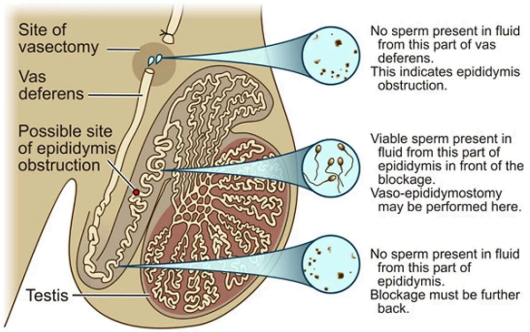

Diagnosis



History: vasectomy, infection, surgery.
Physical exam: presence of vas deferens, epididymal thickening.
Semen analysis: azoospermia with normal volume and pH.
Hormonal profile: Normal FSH, LH, testosterone.
Scrotal ultrasound: May reveal dilation of the epididymis or signs of obstruction.
Testicular biopsy: confirms spermatogenesis if needed.

Causes of obstructive azoospermia

Level	Examples from EAU	Reported proportion
Intra-testicular	Intra-testicular duct obstruction	15%
Epididymal	Infection, trauma, surgery, congenital	30–67%
Vas deferens	Vasectomy, injury, CUAVD / CBAVD	Not quantified
Ejaculatory ducts	Cysts, infection, traumatic, functional	1–5%

Different source denominators may apply: do not add these proportions.

Surgical Treatment Options

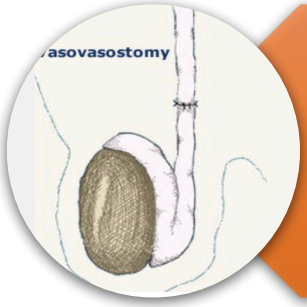

Vasovasostomy (VV): reconnect vas deferens.

- High patency (85–95%) and pregnancy rates (40–70%).
- Success depends on sperm in vasal fluid and time since obstruction.

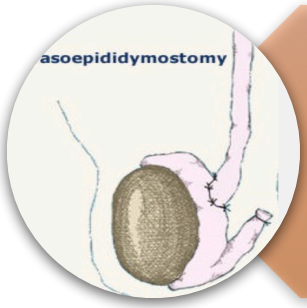

Epididymovasostomy (EV): bypass epididymal blockage.

- Technically demanding, success rate 60–80%.
- Indicated when no sperm in vasal fluid during VV.

Use of **microsurgical technique** is associated with significantly better outcomes and fewer complications (e.g., granuloma, scarring)

RECONSTRUCTION / VASOVASOSTOMY

Vasectomy reversal: EAU outcome ranges

90–97%	52–73%	1.7–4.3
Patency	**Pregnancy**	**Mean months to patency**
Weighted series	Weighted series	Published series

Results depend on obstruction interval, technique and couple factors.

EAU Guidelines on Sexual and Reproductive Health · March 2026 · §11.6.1.b, p.155

RECONSTRUCTION / EPIDIDYMIS

Epididymovasostomy: EAU outcome ranges

63–85%

Patency

Reported series

21–45%

Cumulative natural pregnancy

Reported series

2.8–6.6

Months to patency

Systematic review range

When reconstruction is impossible, retrieve and cryopreserve sperm intraoperatively.

EAU Guidelines on Sexual and Reproductive Health · March 2026 · §11.6.1.b, p.154

Robotic-Assisted Microsurgical (RAVV / RMVE)

High precision anastomosis using robotic instruments.

Reduces need for a skilled microsurgical assistant.Shorter learning curve for novice surgeons.

Excellent patency and pregnancy rates:

RMVV: ~97% patency.

RMVE: ~55% success rate.

Uses high magnification (12x–20x) with robotic + VITOM camera systems.

Allows simultaneous tissue evaluation and suturing

Cost and accessibility

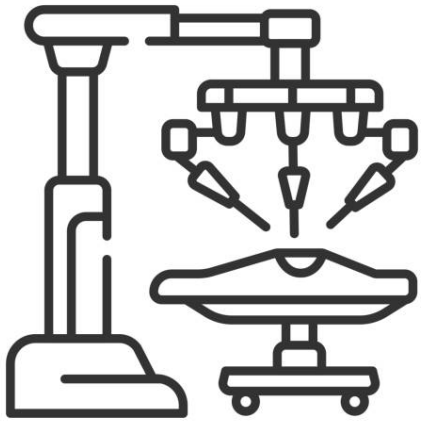

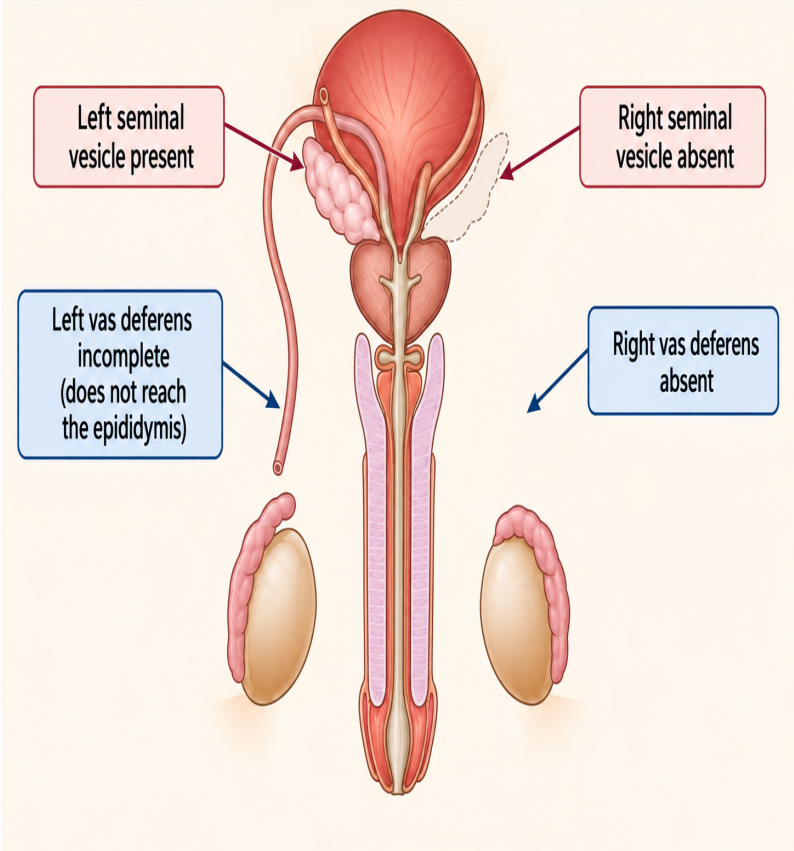
Left seminal vesicle present
Right seminal vesicle absent
Left vas deferens incomplete (does not reach the epididymis)
Right vas deferens absent

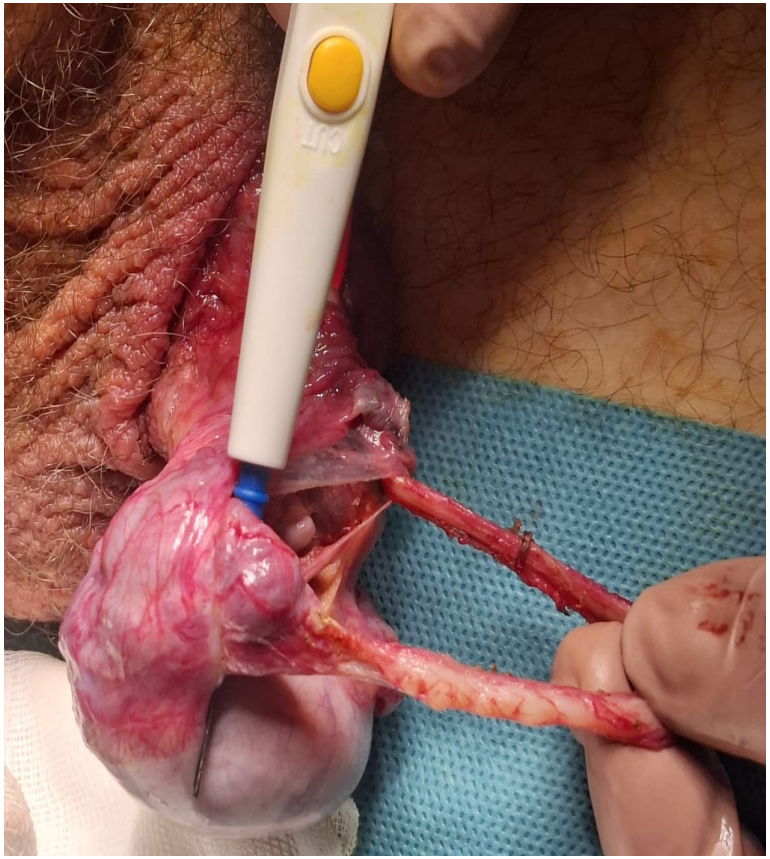





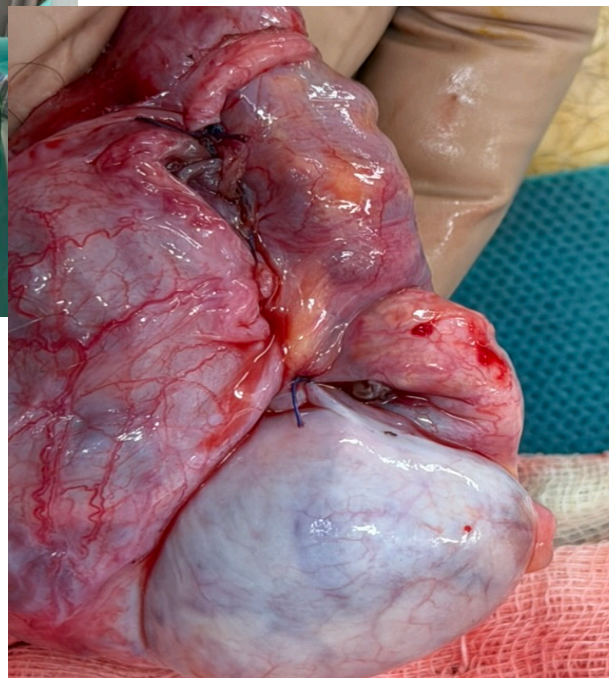

Robotic-Assisted Vasal Reconstruction Summary of Studies

Author	Year	Subjects	N	Study Characteristics	Significant Findings
Schoor	2003	Rats	8	Ex vivo, experienced/ inexperienced surgeons	Tremor eliminated, improved comfort/vision
Kuang	2004	Humans	10	Ex vivo, 5 RAVV vs 5 MAVV	Similar patency, no tremor in RAVV
Fleming	2004	Humans	1	Case report	Demonstrated feasibility
Schiff	2004	Rats	24	In vivo, randomized VV/ VE	Shorter time, equal patency, fewer granulomas (RAVV)
Kuang	2005	Rabbits	4	In vivo, 4 RAVV vs 4 MAVV	Longer time for RAVV, no tremor
Santomauro	2012	Humans	20	In vivo, single/double anastomosis	92% patency, sperm conc. 14M/mL
Parekattil	2012	Humans	155	Retrospective, RAVV vs MAVV	Higher patency in RAVV (96% vs 80%)
Trost	2014	Humans	1	Intracorporeal reversal	Operative time 278 min, no complications
Kavoussi	2015	Humans	52	Retrospective, 25 RAVV vs 27 MAVV	No differences in outcomes
Marshall	2017	Humans	79	RAVV, single-layer anastomosis	88% patency, 192 min op time

Urol Clin N Am 48 (2021) 127–135 https://doi.org/10.1016/j.ucl.2020.09.009

FERTILITAS

Diagnostic procedures:

Testicular biopsy

Testicular sperm aspiration

FERTILITAS

Procedures to improve sperm production:

Varicocele repair

FERTILITAS

Procedures to improve sperm delivery:

Vasectomy reversal

FERTILITAS

Sperm retrieval procedures

vasal aspiration of sperm

Epididymal aspiration of sperm

Open testis biopsy

Testis sperm aspiration & needle biopsy

FERTILITAS

Surgical management of ejaculatory duct obstruction:

Transurethral resection of ejaculatory duct

Transurethral balloon dilatation of ejaculatory duct

Transurethral resection of the ejaculatory ducts: etiology of obstruction and surgical treatment options

Gabriella J. Avellino, M.D.,[a] Larry I. Lipshultz, M.D.,[b] Mark Sigman, M.D.,[a] and Kathleen Hwang, M.D.[c]

[a] Division of Urology, Alpert Medical School of Brown University, Providence, Rhode Island; [b] Division of Male Reproductive Medicine and Surgery, Scott Department of Urology, Baylor College of Medicine Houston, Texas; and [c] Department of Urology, University of Pittsburgh Medical Center, Pittsburgh, Pennsylvania

Clinical suspicion: **Low-volume azoospermia with normal hormone levels, palpable vas deferens, and absent fructose**.

Key imaging tools:

TRUS: Seminal vesicle dilation >1.5 cm, ED diameter >2.3 mm.

MRI: Useful for cystic/soft tissue lesions, but limited availability.

Seminal vesicle aspiration: Diagnostic if sperm are found.

Gold standard: Scrotal vasography (invasive, declining use).

Adjuncts: Vesiculography, chromotubation, manometry.

TABLE 1

Characteristics of categories of ejaculatory duct obstruction.

Parameter	Complete obstruction	Incomplete/partial obstruction	Functional obstructions
Volume of ejaculate	Low	Low-normal	Low
Sperm count	Absent	Low-normal	Absent–low
Sperm motility	Absent	Low	Absent–low
Fructose in ejaculate	Absent	Absent–low	Absent–low
Ejaculate pH	Low	Low–normal	Low–normal
Hormonal evaluation	Normal	Normal	Normal
Seminal vesicle size	Normal–enlarged	Normal–enlarged	Normal–enlarged
Testis size	Normal	Normal	Normal

Avellino. Transurethral resection of ejaculatory ducts. Fertil Steril 2019.

Fertility and Sterility® Vol. 111, No. 3, March 2019 0015-0282/

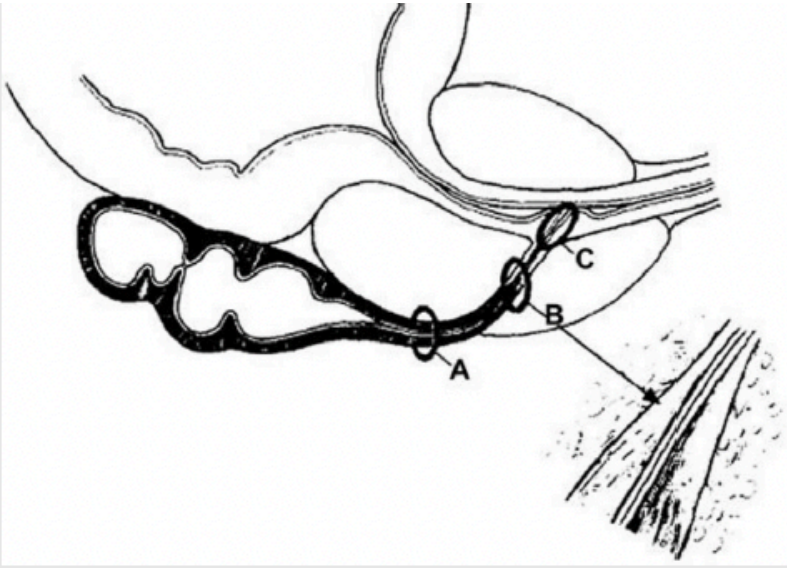

FIGURE 2

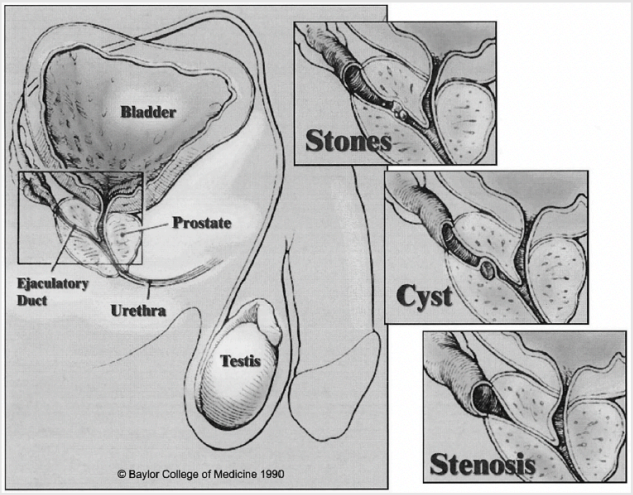

Drawing depicting ejaculatory duct obstruction due to stones, a cyst, and stenosis.

Avellino. Transurethral resection of ejaculatory ducts. Fertil Steril 2019.

FIGURE 3

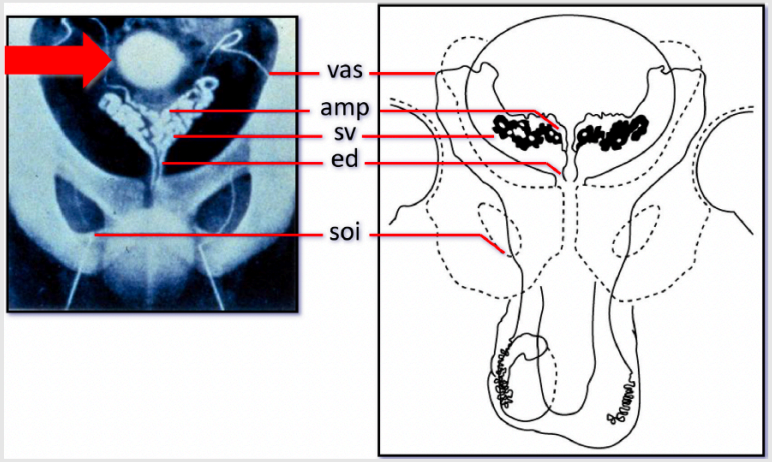

Vasogram showing patent ejaculatory ducts and schematic drawing of the anatomy seen on the vasogram. ed = ejaculatory duct; sv = semin vesicle; vas = vas deferens. (Adapted from Lipshultz LI, Howards SS (eds.). Infertility in the male. New York: Churchill Livingstone, 1983.)

Avellino. Transurethral resection of ejaculatory ducts. Fertil Steril 2019.

FIGURE 4

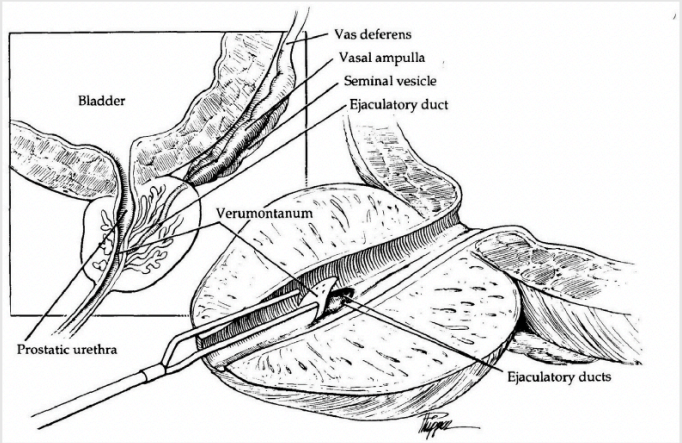

Drawing of endoscopic transurethral loop resection of ejaculatory duct at the verumontanum (From Meacham R, Hellerstein D, Lipshultz L Evaluation and treatment of ejaculatory duct obstruction in infertile men. Fertil Steril 1993; 59:393–7; with permission.)

Avellino. Transurethral resection of ejaculatory ducts. Fertil Steril 2019.

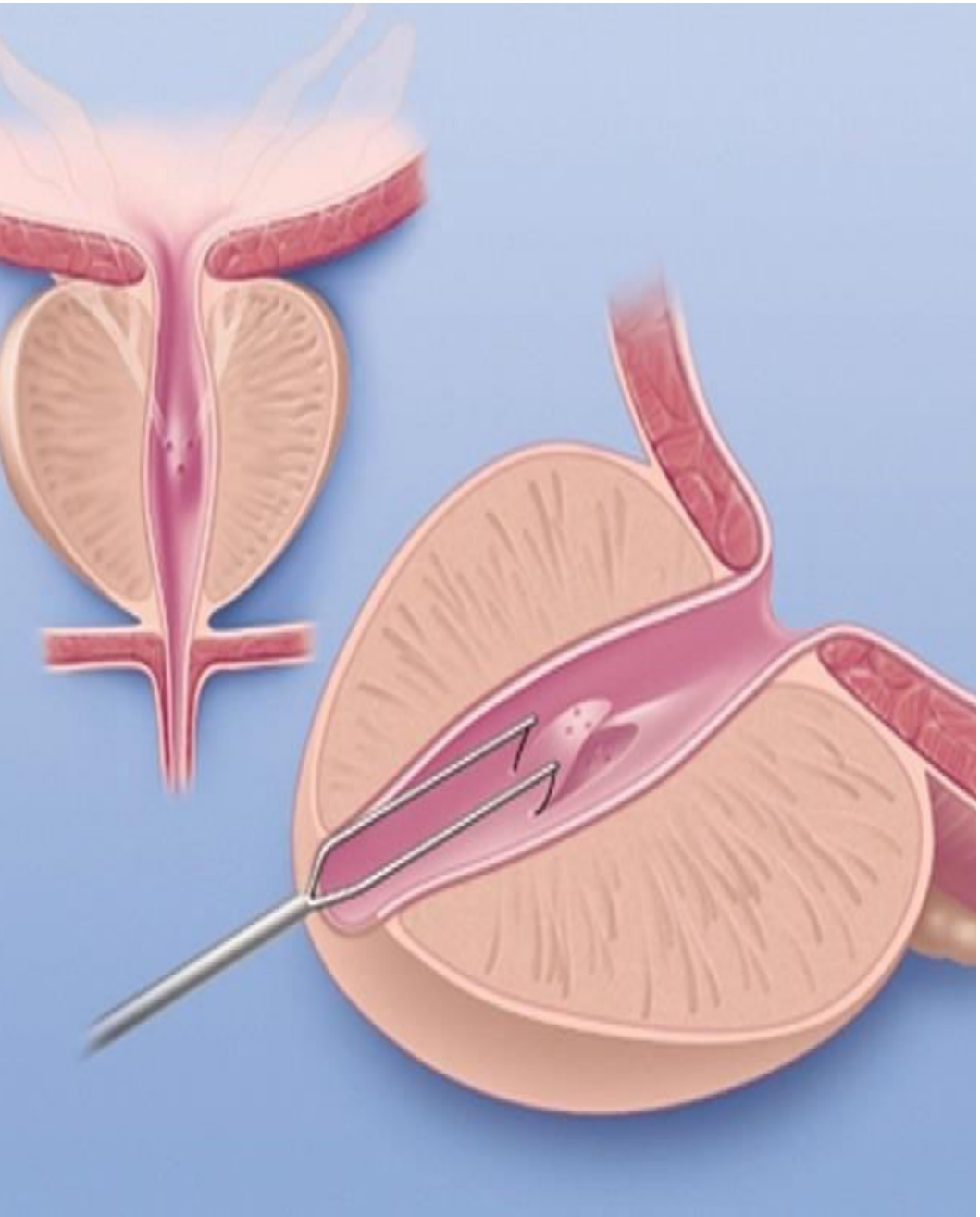

Main Treatment Option – TURED

TURED: Transurethral resection at the verumontanum using a resectoscope.

Adjunctive confirmation: Chromotubation or vasography during surgery.

Outcomes:

- 63–83% improve semen parameters.
- 12.5–31% spontaneous pregnancy rate.
- Better results in partial and cystic EDO vs. complete/acquired types.

COMPLICATIONS:

1. Reflux
2. Epididymitis
3. Retrograde ejaculation

Fertility and Sterility® Vol. 111, No. 3, March 2019 0015-0282/

Male, 38 years old, 4 years of infertility

Female partner, 37 years old, no pregnancies. Refused IVF/ICSI – pursuing natural conception

No varicocele; no systemic symptoms

Progressive deterioration of semen parameters

Semen Analysis Over Time

Date	Sperm (mill/ml)	Motility PR+NP (%)	Morfology (%)	Fructose	Observations
28/05/24	0.515	35 (20+15%)	8	—	cryptozoospermia
08/07/24	0.200	>40	—	—	No morfology assesment

Hormonal Profile

Date	FSH (mUI/ml)	LH (mUI/ml)	Testosterone total (ng/ml)	Estradiol (pg/ml)	SHBG / Albúmina / Libre
28/05/24	3.03	4.71	3.67	—	—
21/08/24	3.66	4.91			

Imaging Findings: TRUS and Ultrasound

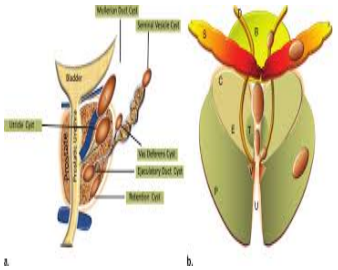

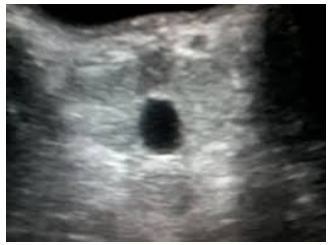

TRUS:

- Dilated seminal vesicles (>1.5 cm)
- **Midline utricular cyst (0.2 ml)**
- Normal prostate size and echotexture

TESTE

- 9 cc

Bilateral intratesticular microlithiasis

No hydrocele, no varicocele visualized

FNA: Left testis: Sertoli-cell only pattern
Right testis Severe hypospermatogenesis.

Diagnostic: Cryptozoospermia due to combined factors: hypospermatogenesis in primary testicular disease with normal FSH levels and obstruction due to utricolar cyst


LED
EndoVue
Falló restablec. :cambiar dispositivo USB
NDS
STORZ
image 1 hub
222010 20
STORZ

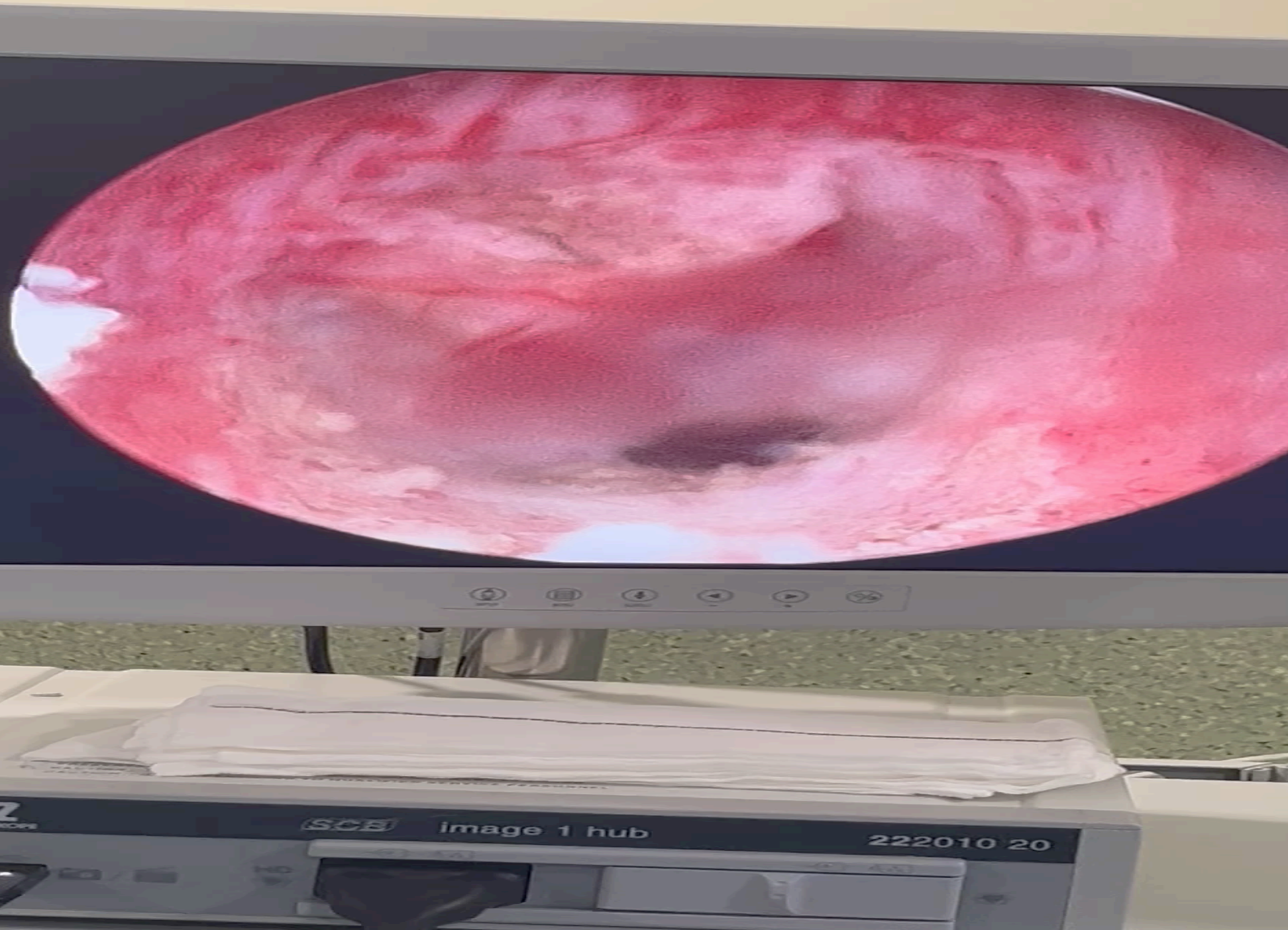
image 1 hub
222010 20

Semen Analysis Over Time

Date	Sperm (mill/ml)	Motility PR+NP (%)	Morfology (%)	Fructose	Observations
28/05/24	0.515	35 (20+15%)	8	—	OAT
08/07/24	0.200	>40	—	—	No morfology assesment
Pos-TURED	**7,56 mill/ml** 26 mill/total	**34+20%**	**1%**	+ Fructosa	

Indicates successful restoration of ductal patency

TURED: what does the evidence actually show?

83%

semen volume improved

62.5%

sperm concentration improved

25%

median spontaneous pregnancy rate

29 studies, mostly observational · 634 men · Very low certainty of evidence

Mekhaimar et al. Turk J Urol 2020;46:335-347. doi:10.5152/tud.2020.20228

Additional treatments for distal obstruction

VESICULOSCOPY	Removal of seminal vesicle debris or calculi
DILATATION / LASER	Balloon dilatation or laser incision in selected calcific lesions
OTHER OPTION	Sperm retrieval plus ICSI if repair is not feasible

Options listed by EAU; the guideline does not provide comparative high-certainty success rates.

Surgical procedures for male infertility: an update

Visser, William R.; Smith-Harrison, L.I.; Krzastek, Sarah C.

Current Opinion in Urology31(1):43-48, January 2021.

doi: 10.1097/MOU.0000000000000828

KEY POINTS

- Microscopic subinguinal varicocelectomy has been shown to have the highest success rates with lowest rates of complications.
- Vesiculoscopy for EDO may allow for temporary dilation of an obstruction long enough to achieve natural conception, while also offering diagnostic capabilities.
- Use of the robotic platform has gained popularity for vasectomy reversals, but controversy remains regarding the cost-effectiveness of this option.
- Reinforcing sutures during vasovasostomy may minimize anastomotic breakdown and reversal failure.
- Gray-scale and color-enhanced ultrasound may improve ability to predict successful sperm retrieval during extraction procedures.

CURRENT OPINION IN UROLOGY

Wolters Kluwer

Copyright © 2025 Wolters Kluwer. Published by Lippincott Williams & Wilkins.

luislopezfando@urolf.com